TENDON INJURIES (BOWED TENDON) IN HORSES

James M. Casey, D.V.M, M.S.
Equine Sports Medicine, Dentistry, & Surgery

Office: (301) 725-4371 Cell: (301) 785-5167
Website: www.equinehorsevet.com

TENDON INJURIES

Tendons are the cable or strap-like structures that attach muscles to the bones on which they act. Most tendons are short and rarely damaged. However, the long tendons of the limbs are very vulnerable to damage during exercise or as a result of direct trauma. The flexor tendons are most important and it is these that are discussed below.

Where are the tendons situated?

The flexor tendons (deep digital flexor tendon, DDFT, and superficial digital flexor tendon, SDFT) run down the back of the leg from the level of the knee (or hock). The SDFT ends on the pastern, the DDFT ends on the lower surface of the coffin bone. At the back of the knee, in the region of the hock and at the level of the fetlock and upper pastern, the tendons are enveloped by a fluid filled sheath. Several strong, short, annular ligaments help to keep the tendons in place in areas of high movement such as joints.

The tendons themselves are composed of longitudinally arranged bundles of dense connective tissue fibers. Blood supply to tendons is poor compared to muscles and other tissues. Because of poor blood supply tendon structures when injured do not heal as well.

Examining a horse's tendon for signs of injury

What are the different types of tendon injury?

Damage to flexor tendons occurs commonly during exercise. Moderately strenuous exercise can result in tearing of fibers in horses that are not fit. Even in fit horses, over stretching of tendons can occur during fast work, work on unleveled ground, work involving jumping at speed, racing, or training. The degree of damage can range from minor, with little fiber damage to very severe with total tendon rupture occurring.

Most often, a proportion of fibers are damaged resulting in a zone of damaged fibers within the body of the tendon. This might form a discreet "hole" (as seen by ultrasound scan) which extends for a variable length of the tendon. A knock to a tendon may result in slight bruising or more severe damage possibly even tendon rupture. Sharp trauma such as a cut can also result in anything from minor damage to severing of the tendon. Injuries involving tendon sheaths are very serious as infection in these structures is potentially life threatening.

Bowed Tendon

What are the first signs of tendon injury?

Damage to a tendon causes inflammation, heat and swelling. Minor fiber damage leads to slight enlargement of the affected part which will feel warmer than the corresponding area on the other limb. Mild strains may not always cause lameness. In severe damage, the limb may become very painful and swollen and the horse may be severely lame. If the tendon is ruptured, the horse may walk with the toe tipped up. If a tendon sheath becomes infected, the horse will also be very lame.

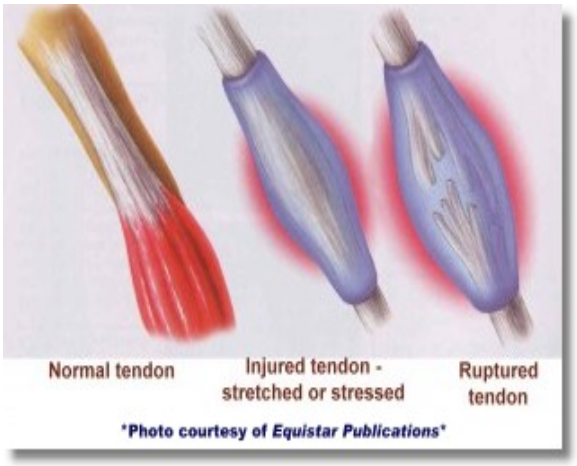

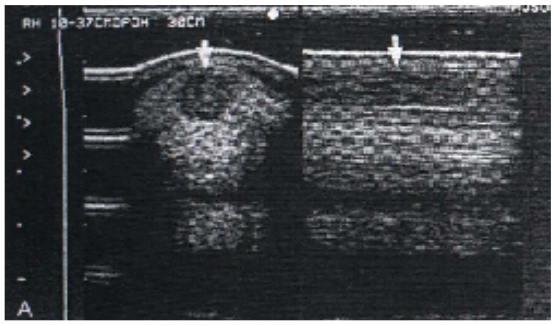

Ultrasound Image
Note: Dark area (indicated with arrow) showing torn tendon fibers.

How can tendon injuries be diagnosed?

If you suspect that your horse has a tendon injury, you should call us immediately. A clinical examination will confirm or deny your concerns. We will look for signs of thickening of the affected tendon(s), heat, pain on palpation etc. It can be difficult to assess the extent of damage by look and feel alone. Ultrasonographic examination – tendon scan – allows visualization of the structure of the tendon and any damage. It also allows assessment of healing processes.

What treatments are available?

In the early stages anti-inflammatory treatment such as the application of cold, support bandaging, anti-inflammation medication such as phenylbutazone is useful. Rest is vital. We will advise whether full stall rest is required for a period of time. Often, we start the controlled exercise immediately. Most tendon injuries require at least 3 months of restricted exercise (e.g. walking in hand or under tack), along with turn out in a paddock may be done if the tendon injuries are not severe. **Controlled exercise is the critical part to maximize the strength and healing of your horse's injured tendon.** Repeated tendon scans are invaluable for assessing healing before exercise levels are increased. It can take up to a year for the tendon to heal.

Injection of bone marrow into a bowed tendon.

We can inject the injured tendon(s) with medications aimed to promote healing. Some of the newer types of medications we are injecting tendons with are: **Platelet Rich Plasma, Stem Cells, and Bone Marrow.** These medications are extracted from the horse that has the injury then injected into the same horse's injured tendon(s). What we are doing here is accessing and augmenting natural processes to enhance healing of the injured tendon(s).

Tendon Injection

Other Types of Tendon Injection Treatments

We can also inject tendons with other compounds including: Hyaluronic Acid, Polysulfated Glycosaminoglycan (PSGAG), Organically Derived Compounds (Dr. Casey's special proprietary formula) that promote healing, etc.

Adjunctive Tendon Therapy

Shockwave Therapy is used also to treat damaged tendons. The science behind Shockwave Therapy is not clear, therefore we consider it as an adjunctive treatment.

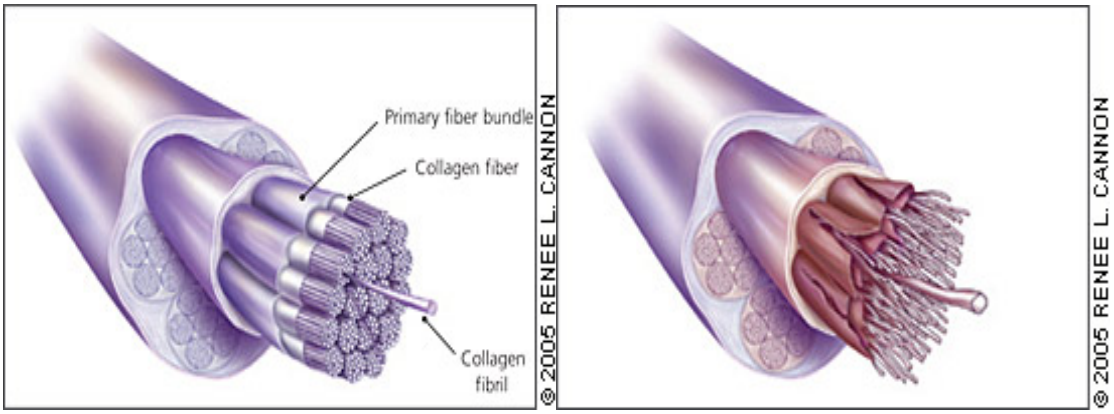

Normal Tendon

Torn Damaged Tendon
Note: the tendon fibers are disoriented

Tendonitis, Bowed Tendon, and Tendon Healing

Tendons are made out of dense connective tissue. When tendon fibers are torn, in order to achieve the best possible healing, controlled and increasing exercise is a critical part to help realign the damaged tendon fibers.

Surgical Treatments: Transecting the Superior Check Ligament

Superficial Digital Flexor Tendon Injuries

Even with optimum healing there is less elasticity in an injured superficial digital flexor tendon (SDFT) resulting in a higher chance of re-injury. Dr. Casey uses the technique of cutting the superior check ligament under general anesthetic allows an extra centimeter or so of give that compensates for the loss of elasticity. Statistics have shown that a thoroughbred racehorse treated conservatively for an SDFT injury still has an 80 % chance of re-injury within the first three races after recovery. Cutting the check ligament reduces the re-injury rate to about 25 %. **All horses that need to pursue athletic careers will greatly benefit from this surgery.**

Controlled Rehabilitation Program and Prognosis

Depending on your type of horse and its use, after a period of rest, your horse should be introduced to a gradually increasing program of exercise which should eventually include trotting and very steady cantering for those type horses. You may not be able to return to as high a level of competition as before the injury but most horses can lead a useful life as a hack or even hunter after tendon injury. Some breeds of horses such as a Standard Bred can often continue racing (after rest and healing) very successfully. Thoroughbred Race Horses can return to racing. However, the success rate is usually less for the Thoroughbred versus the Standard Bred. Eventing and other high performance show horses have, with care, returned to at or near the same level prior to their tendon injuries in my practice.

Equine Sports Medicine, Dentistry, & Surgery
James M. Casey, D.V.M, M.S.
Veterinary Practitioner and Surgeon

Practicing in the Mid-Atlantic States & Florida (MD, VA, DE, PA, NJ, GA, KY, FL) Consults Nationally and Worldwide
Office: 301-725-4371 Cell: 301-785-5167
Email: *casey@us.net* Website: www.equinehorsevet.com